



**Journal Club, 22 Dicembre 2006**

# **Tumore del pancreas: approccio multidisciplinare**

**Alessandro Morandi**  
**Dipartimento Medicina e Geriatria**

**Claudio Codignola**  
**Chirurgia Generale e Toracica**

**Istituto Ospedaliero, Fondazione Poliambulanza**

# **Quell'anemia che...**

**R.R. Journal Club GRG Agosto 2006**



Brescia, 11 agosto 2006

# L'anemia nell'anziano

(ovvero, quel tumore del pancreas che....)

**Renzo Rozzini**

**Dipartimento di Medicina Interna e Geriatria**  
*(Istituto Ospedaliero Poliambulanza)*

**e Gruppo di Ricerca Geriatrica, Brescia**

**Chi era il paziente?**

## **Diagnosi di accettazione (29 Luglio 2006):**

- **Sepsi da verosimile colangite in portatore di protesi biliare per K pancreas**
- **Angina pectoris da discrepanza (anemizzazione? Tachicardia?)**

**73 aa coniugato, abita con la moglie, ha quattro figli viventi.**

**Scolarità elementare, ex operaio ora in pensione.**

**Familiarità per malattie cerebrovascolari.**

**Integrità funzionale e cognitiva.**

# Comorbidità

- **AdenoCa del pancreas (diagnosi nel mese di Aprile 2006: posizionata endoprotesi biliare; III cicli di CHT neoadiuvante con Gemcitabina, ultimo trattamento 29-6-06)**
- **Anemia multifattoriale**
- **Angina pectoris da sforzo a soglia media**
- **Ipertensione arteriosa sistemica grado 1 e rischio aggiuntivo molto alto**
- **Diabete mellito tipo 2 in terapia insulinica**
- **Aterosclerosi carotidea**

## **Storia antecedente**

**Aprile 2006:**

**Accesso DEAS per ittero colestatico:**

**CA 19-9: 2886 (<37U/ml)**

## **TC ADDOME Aprile 2006**

**Indagine condotta con tecnica spirale.**

- **Lesione che occupa la testa ed il corpo del pancreas con parziale estensione verso il tratto prossimale della coda (atrofica).**
- **Stretto contatto con l'estremo prossimale della vena mesenterica superiore (pervia) e con l'oliva portale che risulta parzialmente avvolta dalla lesione.**
- **Stretto contatto con l'origine dell'arteria epatica dal tripode celiaco.**
- **Pervia l'arteria mesenterica superiore sin.**

## **COLANGIO-WIRSUNGRAFIA RETROGRADA (Aprile 2006)**

**Impianto di endoprotesi biliare.**

**CITOLOGIA: AdenoCa duttale.**

## Staging

Table 1

American Joint Committee on Cancer (AJCC)  
TNM Staging of Pancreatic Cancer (2002)

Because only a few patients with pancreatic cancer undergo surgical resection of the pancreas (and adjacent lymph nodes), a single TNM classification must apply to both clinical and pathologic staging.

## Primary Tumor (T)

- TX** Primary tumor cannot be assessed
- T0** No evidence of primary tumor
- Tis** Carcinoma *in situ*\*
- T1** Tumor limited to the pancreas, 2 cm or less in greatest dimension
- T2** Tumor limited to the pancreas, more than 2 cm in greatest dimension
- T3** Tumor extends beyond the pancreas but without involvement of the celiac axis or the superior mesenteric artery
- T4** Tumor involves the celiac axis or the superior mesenteric artery (unresectable primary tumor)

\*This also includes the "PanInIII" classification.

## Regional Lymph Nodes (N)

- NX** Regional lymph nodes cannot be assessed
- N0** No regional lymph node metastasis
- N1** Regional lymph node metastasis

## Distant Metastasis (M)

- MX** Distant metastasis cannot be assessed
- M0** No distant metastasis
- M1** Distant metastasis

## Stage Grouping

<b>Stage 0</b>	Tis	N0	M0
<b>Stage IA</b>	T1	N0	M0
<b>Stage IB</b>	T2	N0	M0
<b>Stage IIA</b>	T3	N0	M0
<b>Stage IIB</b>	T1	N1	M0
	T2	N1	M0
	T3	N1	M0
<b>Stage III</b>	T4	Any N	M0
<b>Stage IV</b>	Any T	Any N	M1

Used with the permission of the American Joint Committee on Cancer (AJCC), Chicago, Illinois. The original and primary source for this information is the AJCC Cancer Staging Manual, Sixth Edition (2002) published by Springer-Verlag New York. (For more information, visit [www.cancerstaging.net](http://www.cancerstaging.net).) Any citation or quotation of this material must be credited to the AJCC as its primary source. The inclusion of this information herein does not authorize any reuse or further distribution without the expressed, written permission of Springer-Verlag New York, Inc., on behalf of the AJCC.

[STAGING CONTINUED ON ST-2](#)

## **TC addome 25 Luglio 2006**

- **Endoprotesi biliare.**
- **Riduzione volumetrica della lesione solida eteroplastica segnalata nella testa del pancreas (1,5 – 2 cm nel piano assiale).**
- **Retrodilatazione del Wirsung.**
- **La lesione circonda l'oliva portale stenotica, ma ancora pervia.**
- **Pervi il sistema venoso spleno-mesenterico-portale e la vena cava inferiore.**
- **Non macroadenopatie.**

## Staging

Table 1

American Joint Committee on Cancer (AJCC)  
TNM Staging of Pancreatic Cancer (2002)

Because only a few patients with pancreatic cancer undergo surgical resection of the pancreas (and adjacent lymph nodes), a single TNM classification must apply to both clinical and pathologic staging.

## Primary Tumor (T)

**TX** Primary tumor cannot be assessed

**T0** No evidence of primary tumor

**Tis** Carcinoma *in situ*\*

**T1** Tumor limited to the pancreas, 2 cm or less in greatest dimension

**T2** Tumor limited to the pancreas, more than 2 cm in greatest dimension

**T3** Tumor extends beyond the pancreas but without involvement of the celiac axis or the superior mesenteric artery

**T4** Tumor involves the celiac axis or the superior mesenteric artery (unresectable primary tumor)

\*This also includes the "PanInIII" classification.

## Regional Lymph Nodes (N)

**NX** Regional lymph nodes cannot be assessed

**N0** No regional lymph node metastasis

**N1** Regional lymph node metastasis

## Distant Metastasis (M)

**MX** Distant metastasis cannot be assessed

**M0** No distant metastasis

**M1** Distant metastasis

## Stage Grouping

**Stage 0** Tis N0 M0

**Stage IA** T1 N0 M0

**Stage IB** T2 N0 M0

**Stage IIA** T3 N0 M0

**Stage IIB** T1 N1 M0

T2 N1 M0

T3 N1 M0

**Stage III** T4 Any N M0

**Stage IV** Any T Any N M1

Used with the permission of the American Joint Committee on Cancer (AJCC), Chicago, Illinois. The original and primary source for this information is the AJCC Cancer Staging Manual, Sixth Edition (2002) published by Springer-Verlag New York. (For more information, visit [www.cancerstaging.net](http://www.cancerstaging.net).) Any citation or quotation of this material must be credited to the AJCC as its primary source. The inclusion of this information herein does not authorize any reuse or further distribution without the expressed, written permission of Springer-Verlag New York, Inc., on behalf of the AJCC.

[STAGING CONTINUED ON ST-2](#)

## **Riduzione del CA 19.9 (521 → 258)**

**In considerazione dell'efficacia della PKT neoadiuvante, e della valutazione oncologica che dà una prognosi superiore a sei mesi, si richiede **valutazione cardiologica** per coronarografia ed eventuale stenting (che permetterebbe al paziente di essere sottoposto ad intervento chirurgico).**

**ECO-Cardiogramma da Sforzo: test sottomassimale con scarso incremento cronotropo (da B-bloccante? da malattia ischemica plurivasale?).**

**Coronarografia: malattia trivasale (senza stenosi critiche).**

## **Valutazione CCH: Coronaropatia trivasale.**

**In considerazione della gravità del quadro npl con indicazione ad intervento sollecito e della non criticità delle lesioni a carico dei vasi coronarici principali, non si ritiene indicato trattamento di rivascularizzazione.**

**8 Agosto 2006:**

**Consulto con oncologo, chirurgo, anestesista; si propongono al paziente e familiari le possibili opzioni terapeutiche e i possibili rischi (IMA, ictus...).**

**Il paziente opta per procedura chirurgica.**

**Valutazione anestesiológica:** Rischio anestesiológico nettamente aumentato. Si accetta quindi il paziente con definizione **ASA 4** (rischio molto elevato: grave malattia in atto con pericolo di vita), previo colloquio informato ed esplicito con il paziente ed i parenti riguardo le possibili complicanze intra e post-operatorie. Indispensabile verifica posti letto in TIP.

Paziente dimesso; **previsto ricovero dopo 7 giorni in Chirurgia.**

## **Diagnosi di dimissione:**

- **AdenoCa del pancreas (Diagnosi Aprile 2006; endoprotesi biliare e CHT neoadiuvante con Gemcitabina)**
- **Colangite acuta**
- **Anemizzazione multifattoriale (eseguita emotrasfusione di 4 Unità di Emazie)**
- **Angina da discrepanza in coronaropatia trivasale**
- **Ipertensione arteriosa sistemica grado 1 e rischio aggiuntivo molto alto**
- **Aterosclerosi carotidea**
- **Diabete mellito tipo 2 in terapia insulinica**

**Ricovero previsto presso l'Unità di  
Chirurgia Generale 16 Agosto 2006**

**Benessere dalla dimissione dal nostro reparto (8 Agosto 2006).**

**14 Agosto 2006:** accede al DEAS del nostro ospedale per la comparsa nella notte febbre (T 39 °C) con brividi scuotenti e vomito alimentare.

# Ricovero in geriatria

- **Sepsi da**
- **Colangite acuta**
- **AdenoCa del pancreas**
- **Coronaropatia trivasale**

**16 Agosto 2006 Trasferimento in  
Chirurgia**

# **Dal 17 al 20 Agosto stazionarietà clinica**

- **Es Ematici: Hb 12.10, Bil.Tot 1.49, AST 45, ALT 69, ALP 1068, Gamma-GT 1109, CA 19-9 1164 (ultimo valore 258)**
- **Emotrasfuse 2 unità di E.C**

## **21 Agosto 2006: Intervento chirurgico**

**Laparotomia esplorativa. Idrope della colecisti (eseguita colecistectomia).  
Estesa infiltrazione neoplastica del tripode celiaco sino all'ilo splenico, con infiltrazione dell'oliva portale. Esame istologico estemporaneo (Adenoca).**

**Regolare decorso clinico postoperatorio.**

**In data 29 Agosto 2006** dimissione dal  
Reparto di Chirurgia e controllo  
programmato dopo 15 giorni presso  
**Oncologia** (V.O.: non ulteriori indicazioni  
a PKT in considerazione della diffusione  
della malattia e del peggioramento del  
Performance Status).

# Follow up

**Paziente è deceduto dopo un mese dalla dimissione dal reparto di Chirurgia.**

# **L'iter diagnostico-terapeutico nelle linee guida**



## **Guidelines for the management of patients with pancreatic cancer periampullary and ampullary carcinomas**

Pancreatic Section of the British Society of Gastroenterology, Pancreatic Society of Great Britain and Ireland, Association of Upper Gastrointestinal Surgeons of Great Britain and Ireland, Royal College of Pathologists, Special Interest Group for Gastro-I

***Gut 2005;54(Suppl V):v1-v16.***

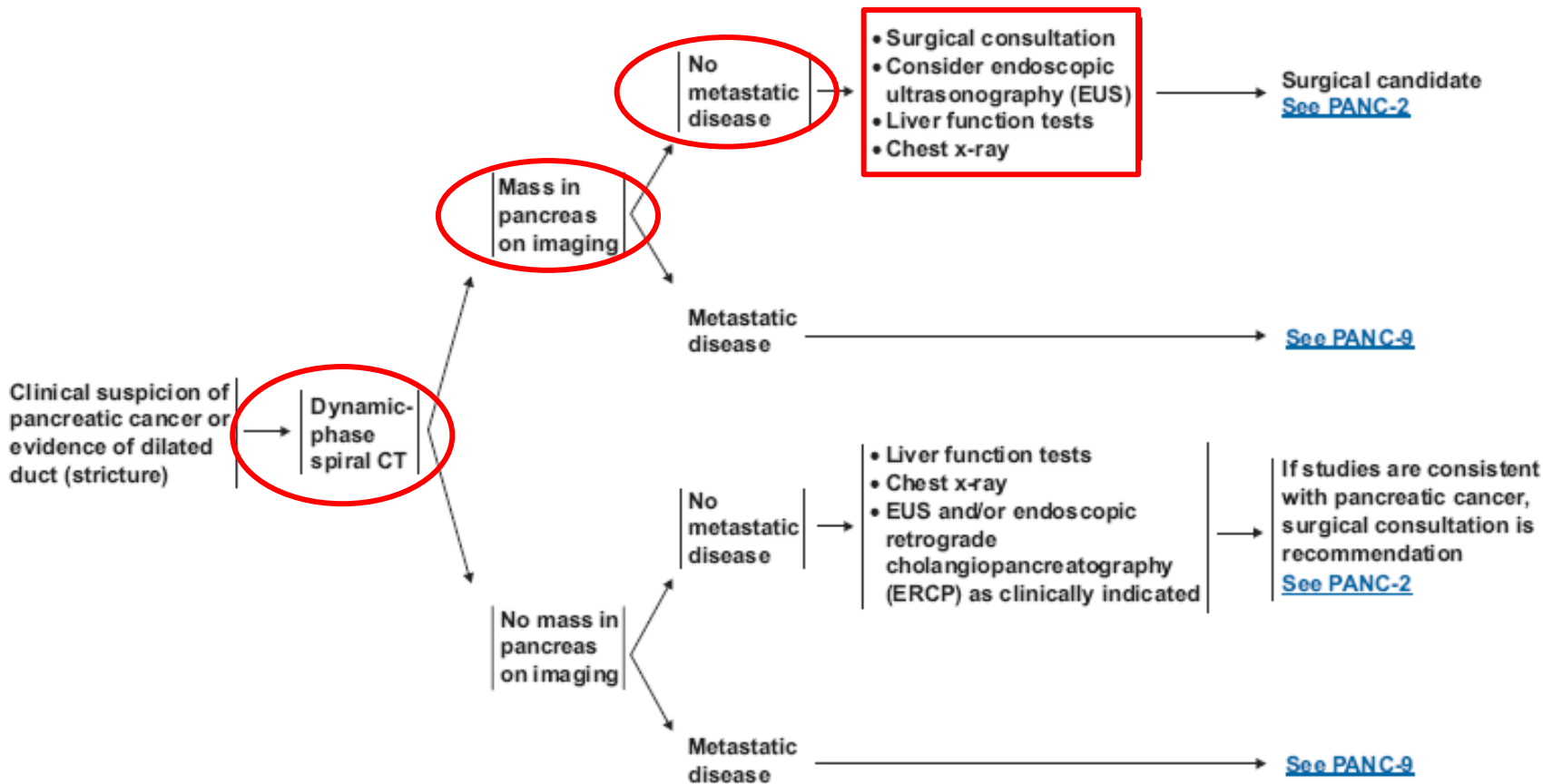
## Recommendations

- Clinical presentation suggesting cancer of the pancreas should lead without delay to ultrasound of the liver, bile duct, and pancreas (grade B).
- When the diagnosis of pancreatic malignancy is suspected from clinical symptoms and/or abdominal ultrasound findings, the selective use of computerised tomography (CT), endoscopic retrograde cholangiopancreatography (ERCP), and/or magnetic resonance (MR), including magnetic resonance cholangiopancreatography (MRCP) and occasionally magnetic resonance angiography (MRA), will accurately delineate tumour size, infiltration, and the presence of metastatic disease in the majority of cases (grade B).
- Where available, endosonography and/or laparoscopy with laparoscopic ultrasonography may be appropriate in selected cases (grade B).

**Work up of patient with suspected pancreatic cancer.**

CLINICAL  
PRESENTATION

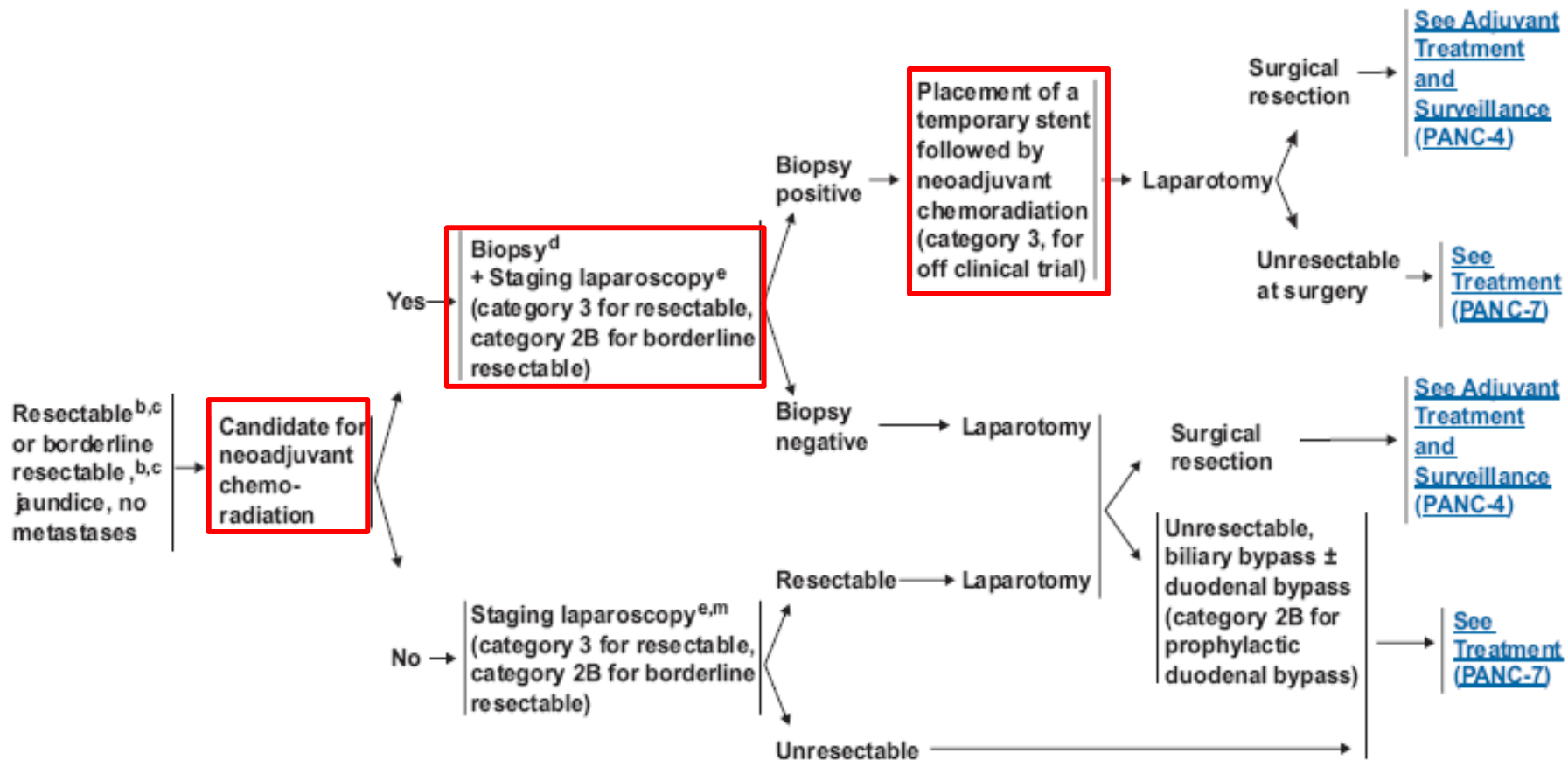
WORKUP



CLINICAL  
PRESENTATION

WORKUP

TREATMENT



# Principles of surgery

- Decisions about diagnostic management and resectability should involve **multidisciplinary consultation** with reference to appropriate radiographic studies to evaluate extent of disease.
- Resections should be done at **institutions that perform** a large number of pancreatic resections annually.

- **Endoscopic ultrasound (EUS)** may be complimentary to CT.
- **Diagnostic staging laparoscopy** to rule out subradiological metastases is used routinely in some situations prior to surgery or chemoradiation, or selectively in patients who are at higher risk of disseminated disease, such as with borderline resectable disease or poor prognostic factors (e.g. markedly elevated CA19-9 or large, bulky primary tumor).

# Criteria for resectability status

## RESECTABLE

### • HEAD/BODY/TAIL

- No distant metastases
- Clear fat plane around celiac and superior mesenteric arteries (SMA)
- Patent superior mesenteric vein (SMV)/portal vein

## BORDERLINE RESECTABLE<sup>1</sup>

### • HEAD/BODY

- Severe unilateral SMV/portal impingement
- Tumor abutment on SMA
- Gastroduodenal artery (GDA) encasement up to origin at hepatic artery
- Tumors briefly involving the IVC
- SMV occlusion, if of a short segment, with open vein both proximally and distally (If the proximal SMV were occluded up to the portal vein branches then it would be unresectable)
- Colon or mesocolon invasion

### • TAIL

- Adrenal, colon or mesocolon, or kidney invasion (category 2B)
- Preoperative evidence of biopsy-positive peripancreatic lymph node

## UNRESECTABLE

### • HEAD

- Distant metastases (includes celiac and/or para-aortic) (category 2B)
- SMA, celiac encasement
- SMV/portal occlusion
- Aortic, Inferior vena cava (IVC) invasion or encasement
- Invasion of SMV below transverse mesocolon

### • BODY

- Distant metastases (includes celiac and/or para-aortic) (category 2B, Body and tail lesions that have positive celiac and/or paraaortic nodes in close vicinity to the primary may also be borderline rather than unresectable)
- SMA, celiac, hepatic encasement
- SMV/portal occlusion
- Aortic invasion

### • TAIL

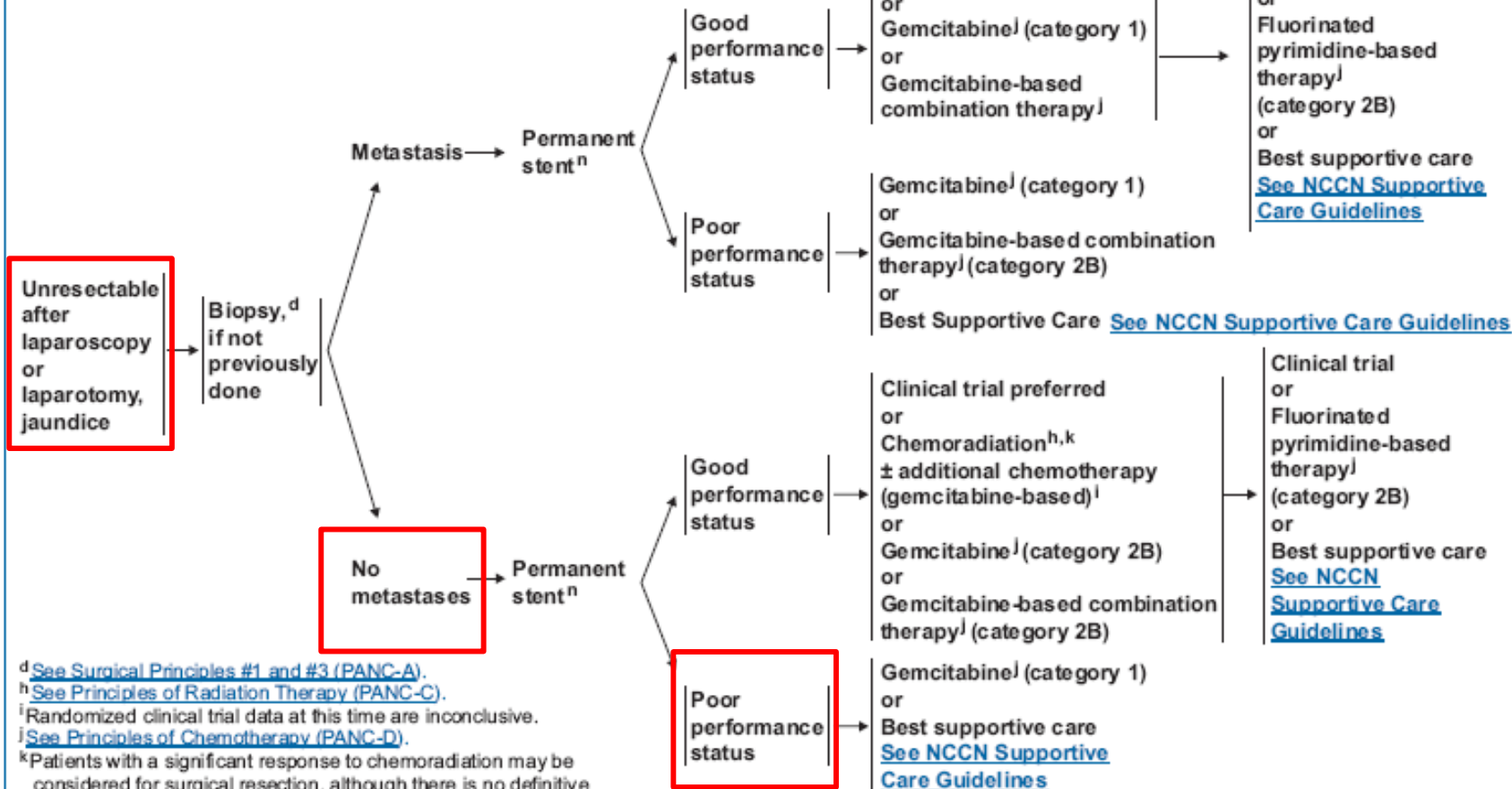
- Distant metastases (includes celiac and/or para-aortic) (category 2B, Body and tail lesions that have positive celiac and/or paraaortic nodes in close vicinity to the primary may also be borderline rather than unresectable)
- SMA, celiac encasement
- Rib, vertebral invasion

CLINICAL  
PRESENTATION

WORKUP

TREATMENT

SALVAGE THERAPY



<sup>d</sup> See [Surgical Principles #1 and #3 \(PANC-A\)](#).

<sup>h</sup> See [Principles of Radiation Therapy \(PANC-C\)](#).

<sup>i</sup> Randomized clinical trial data at this time are inconclusive.

<sup>j</sup> See [Principles of Chemotherapy \(PANC-D\)](#).

<sup>k</sup> Patients with a significant response to chemoradiation may be considered for surgical resection, although there is no definitive evidence at this time to support this intervention.

<sup>n</sup> Unless biliary bypass performed at time of laparoscopy or laparotomy.

**Sarebbe stato possibile evitare la  
laparotomia?**

## **Le metodiche diagnostiche hanno la stessa specificità e sensibilità?**

- **TC**
- **RM, AngioRM**
- **CPRE**
- **Ecografia (endoscopica, laparoscopica)**
- **Laparoscopia**

**Sensitivity and specificity of computed tomography (CT), endoscopic ultrasound (EUS), laparoscopic ultrasound (LUS) and intraoperative ultrasound (IOUS) for staging pancreatic cancer.**

Method	Years	Mean sensitivity (%)	Mean specificity (%)
CT	2002, 2004	90	99
EUS	1999, 2004	77	96
LUS	1999	78	100
IOUS	1993,1999	93	89

*Surgical Oncology 2005;14:105-113.*

**Qual è l'attuale gold standard  
diagnostico ?**

**Come evitare laparotomie inutili (in  
particolare nei casi con elevata  
comorbilità?)**

# **Nuovi strumenti**

- **TC multi-slice**
- **(Laparoscopia)**
- **Ecografia laparoscopica**

# TC multi-slice

- **Molti software dedicati (pancreas protocols, 3-D, multidetector, ecc)**
- **Sensibilità  $\approx 90\%$ , specificità  $\approx 99\%$**
- **Immagini 2D e 3D ad alta risoluzione**
- **NON operatore dipendente**
- **Minimamente invasiva**

# Vascular involvement assessed by CT scanning

**Table 1** Definition of vascular involvement assessed by CT scanning

<b>Grade of resectability</b>	<b>Definition</b>
Grade 0	Biliary and pancreatic duct dilatation without a mass present (addition)
Grade A	Fat plane separates the tumour and/or the normal pancreatic parenchyma from adjacent vessels
Grade B	Normal parenchyma separates the hypodense tumour from adjacent vessels
Grade C	Hypodense tumour is inseparable from adjacent vessels, and the points of contact form a convexity against the vessels
Grade D	Hypodense tumour is inseparable from adjacent vessels, and the points of contact form a concavity against the vessels or partially encircle the vessels
Grade E	Hypodense tumour encircles adjacent vessels, and no fat plane is identifiable between the tumour and the vessels
Grade F	Tumour occludes the vessels

Based on the classification of vascular involvement described by Loyer *et al* (1996).

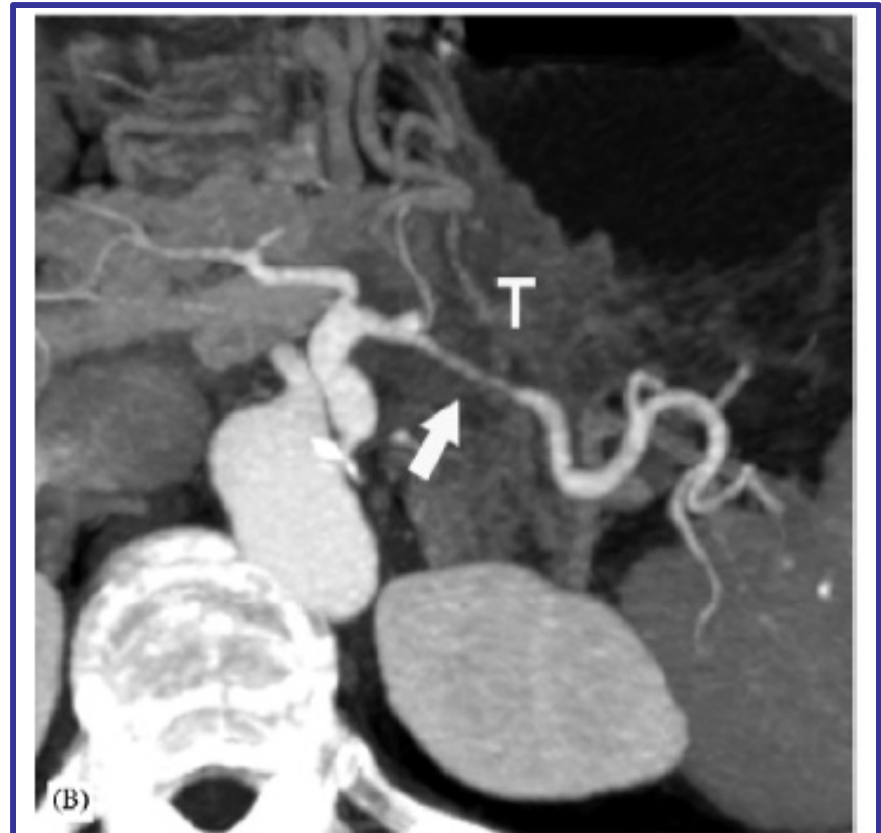
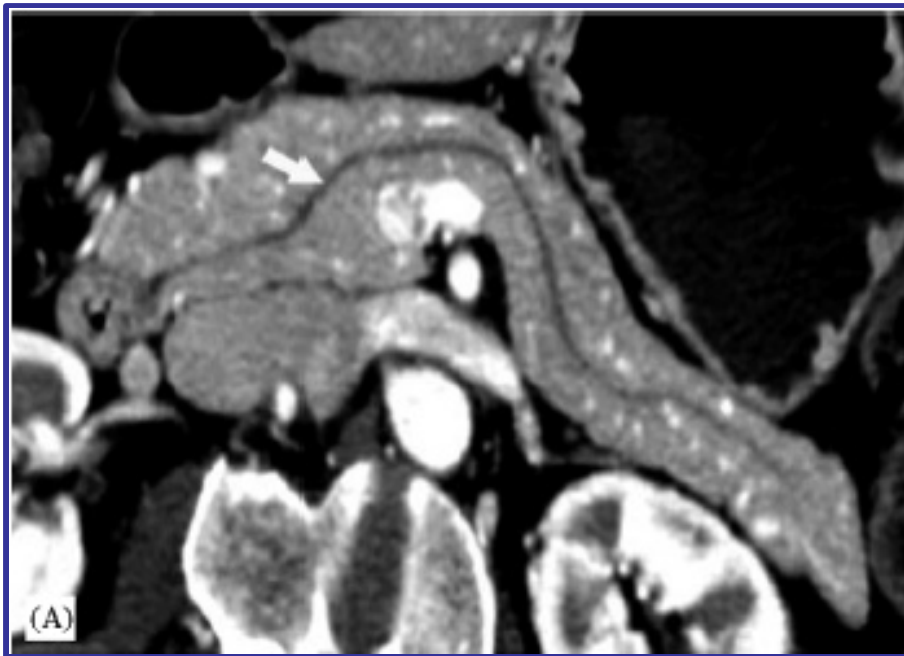
Fig. 1. A and B: High-resolution pancreatic protocol computed tomography (CT) of normal pancreas and pancreatic cancer. (A) curved planar reformation of the normal pancreas with a normal pancreatic duct (arrow). (B) Maximum intensity image demonstrates pancreatic tumor (T) in tail of the pancreas encasing the splenic artery (arrow).

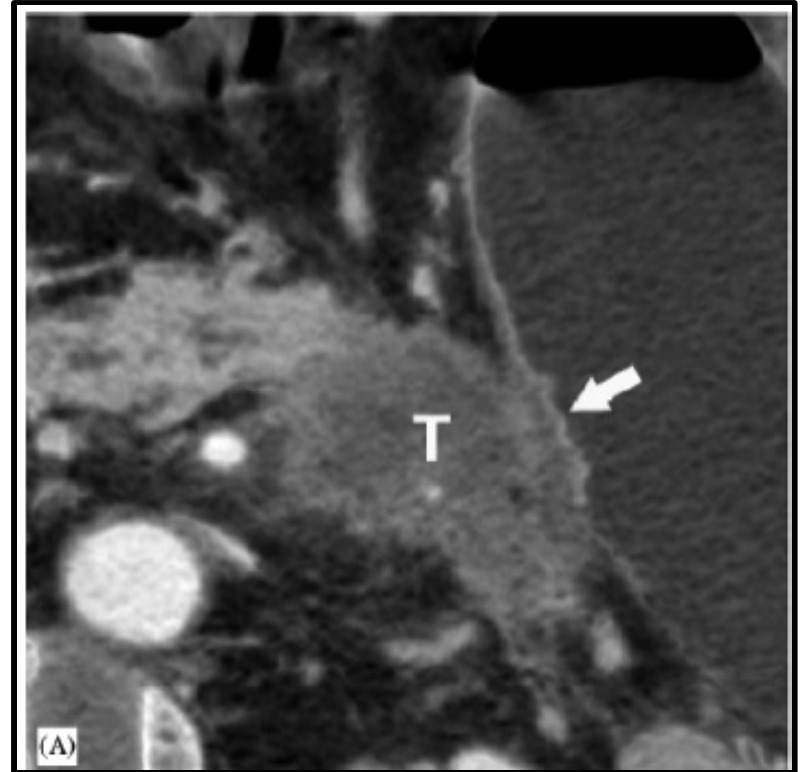
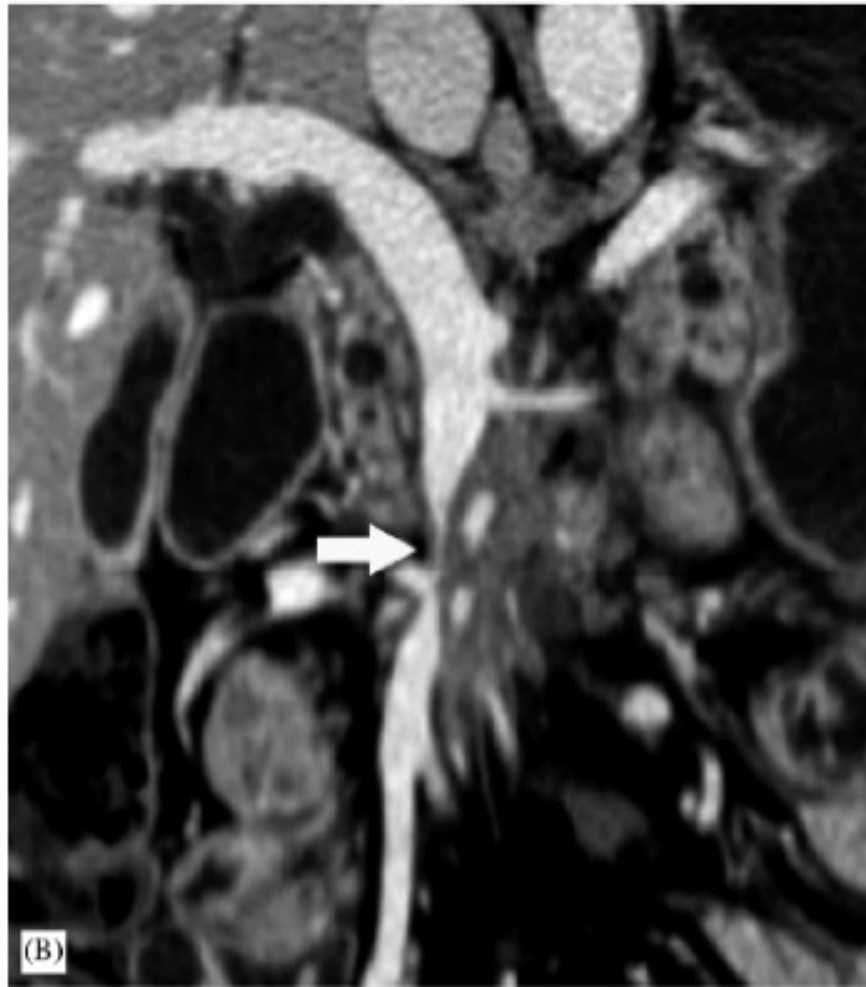

Fig. 3. A and B: Pancreatic protocol CTs of unresectable pancreatic carcinomas. (A) Minimum intensity image of a pancreatic tumor (T) in the tail of the pancreas invading the body of the stomach (arrow). (B) curved planar reformation of the superior mesenteric vein demonstrating circumferential encasement

# Ecografia laparoscopica

- **Non laparoscopia da sola! (Manca valutazione tattile)**
- **OPERATORE DIPENDENTE**
- **Invasiva**
- **Necessarie manovre chirurgiche per uno studio accurato**
- **Apparecchiature e personale dedicato**

# **Ecografia laparoscopica - Tecnica**

- **Preparazione accessi (5 e 10 mm)**
- **Esame del fegato (segmento laterale sinistro, lobo destro)**
- **Scansione trasversale del legamento epatoduodenale**
- **Identificazione dell'arteria mesenterica superiore, vena porta e vena splenica**
- **Esame del pancreas**
- **Tumore**

**Table 1.** Value of staging laparoscopy in the staging of pancreatic cancer patients

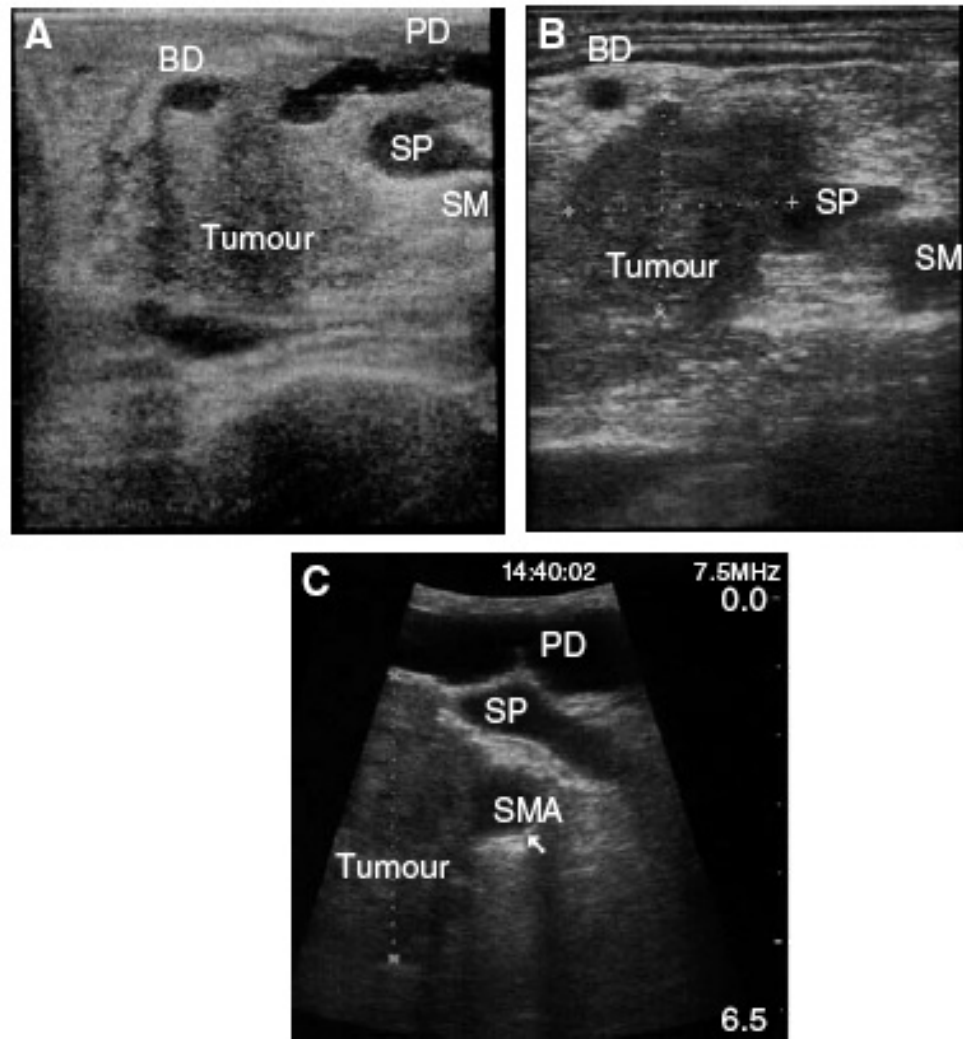
Study, publication year	Study period	Study type	n <sup>a</sup>	Preoperative imaging studies	Procedure	Tumor location (%)	Unresectable patients found during staging laparoscopy (%)	Additional unresectable found during laparotomy (%)	Total unresectable patients (%)	Patients spared laparotomy (%)
Conlon [19], 1996	1992–1994	Prosp.	115	Dynamic CT, US, ERCP	Lap	64 HU, 25 BT	36	5	41	36
Pietrabissa [75], 1999	1994–1998	NS	42 (50)	High quality CT	Lap + LUS	72 HU, 28 BT	24	7	31	24
Velasco [25], 2000	NS	Prosp.	33 (77)	Spiral CT, MRI, US, ERCP	Lap + LUS	NS	51	6	57	27
Jimenez [23], 2000	1994–1998	Retro.	125	Spiral CT, angiogram	Lap + per. washings	62 HU, 38 BT	31	6	37	31
Schachter [20], 2000	1996–1999	Prosp.	67 (94)	High quality CT, US, EUS	Lap + LUS	67 HU, 28 BT	45	6	51	31
Menack [61], 2001	1994–1997	Retro.	27	High quality CT, US, ERCP	Lap + LUS	78 HU, 11 BT	26	7	33	NS
Vollmer [38], 2002	1996–1999	Retro.	88 (157)	High quality CT	Lap + LUS <sup>b</sup>	86 HU, 14 BT	30	15	46	30
Doran [17], 2004	1997–2002	Prosp.	190 <sup>c</sup> (305)	Helical CT, US, ERCP, EUS, angiogram	Lap + LUS	NS	15	16	31	10

<sup>a</sup>Number of patients with pancreatic adenocarcinoma; number in parenthesis refers to the total number of patients.

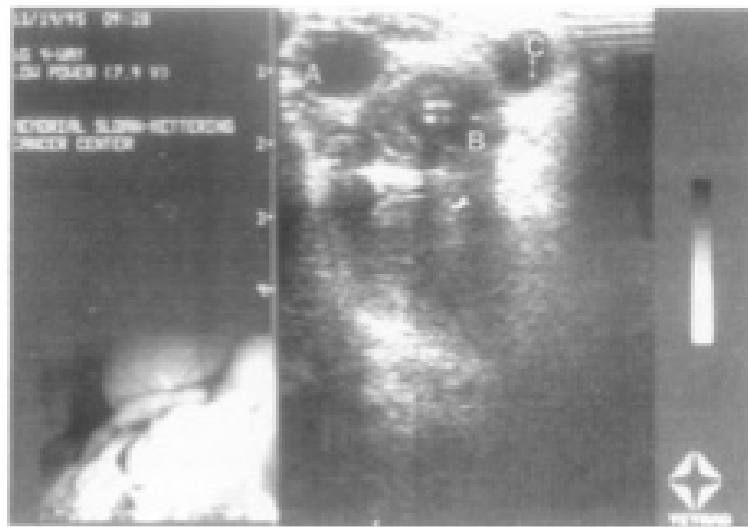
<sup>b</sup>Only 55% of patients had LUS.

<sup>c</sup>Includes also patients with periampullary tumors; 93 of the 305 patients (30.5%) had pancreatic adenocarcinoma but the results are not specific to them.

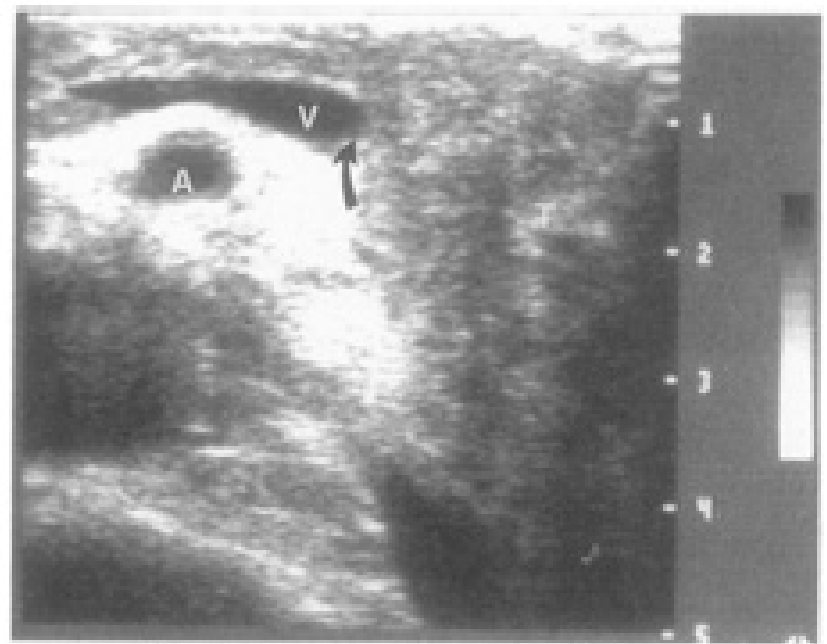
Prosp., prospective study; NS, not stated; Retro., retrospective study; CT, computed tomography; US, ultrasound; ERCP, endoscopic retrograde cholangiopancreatography; MRI, magnetic resonance imaging; EUS, endoscopic ultrasound; Lap, laparoscopy; LUS, laparoscopic ultrasound; per., peritoneal; HU, pancreatic head or uncinate process; BT, pancreatic body or tail.



**Figure 1** Laparoscopic ultrasound assessment of vascular invasion. **(A)** Resectable tumour free from splenoportal junction. **(B)** Tumour involvement of splenoportal junction. **(C)** Tumour involvement of the superior mesenteric artery (BD – bile duct, PD – pancreatic duct, SP – splenoportal junction, SMA – superior mesenteric artery).



**Figure 1.** Transverse image of the hepatoduodenal ligament. The portal vein (A) and hepatic artery (C) can clearly be seen. A distended bile duct with a biliary stent is also visualized (B).



**Figure 2.** An uncinate tumor (T) is demonstrated involving the portal vein (V) at its junction with the splenic vein. The superior mesenteric artery (A) is also demonstrated with its characteristic halo of hyperchoic fat.

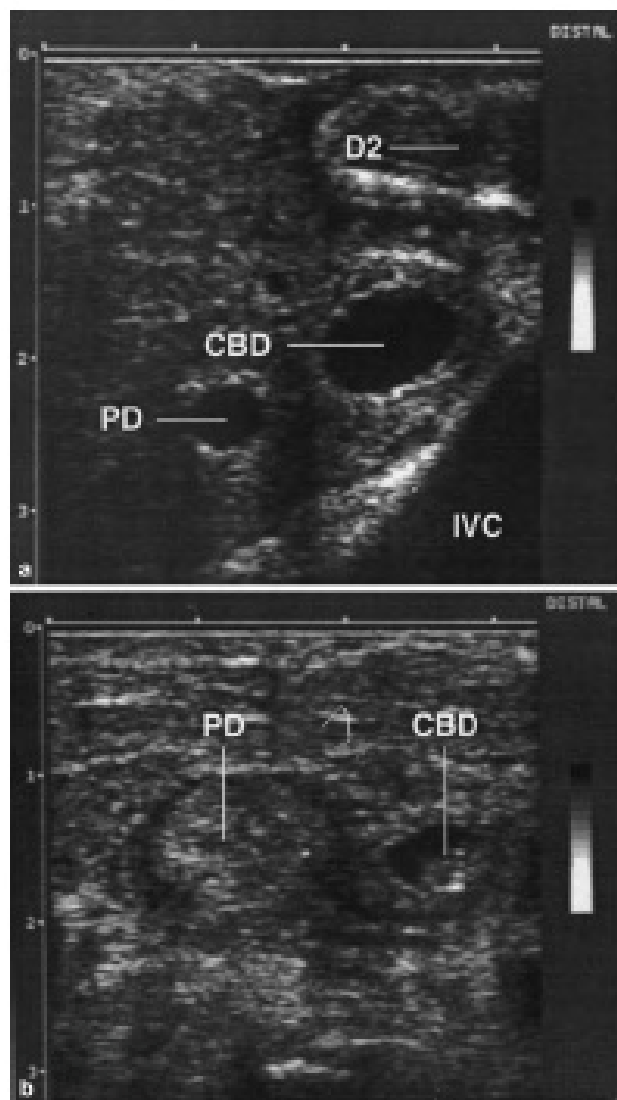


Fig. 1. Laparoscopic ultrasound scans of a patient presenting with obstructive jaundice secondary to a periampullary tumor. a. This transverse scan through the head of the pancreas shows a prominent lower common bile duct (CBD) and pancreatic duct (PD), the second part of the duodenum (D2), and inferior vena cava (IVC). b. This image, which is proximal to the ampulla, demonstrates a tumor infiltrating the pancreatic duct and within the lumen of the lower common bile duct.

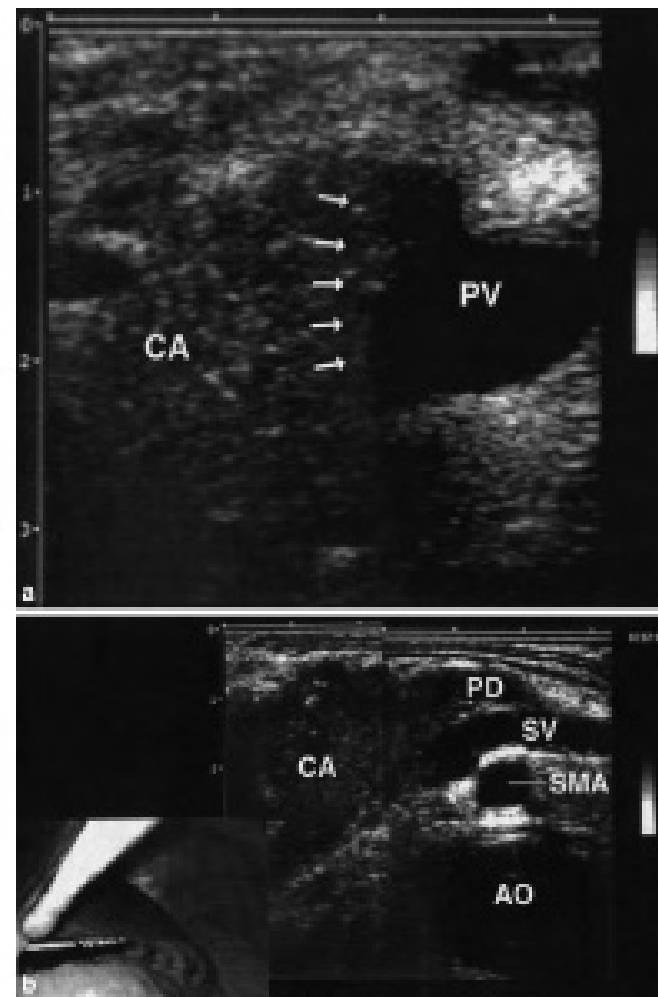


Fig. 2. Transverse laparoscopic ultrasound images of a patient presenting with an apparently resectable carcinoma of the head of the pancreas on CT scan. a. The pancreatic cancer (CA) is hypoechoic relative to the surrounding tissues. There is apparent infiltration (arrows) within the portal vein (PV). b. This composite image shows the transducer placed on the antrum of the stomach underneath the left lobe of the liver. The hypoechoic tumor (CA), which measured approximately 3 cm in maximal diameter, extended across the neck of the pancreas toward a dilated pancreatic duct (PD). The splenic vein (SV) and superior mesenteric artery (SMA) lie anterior to the aorta (AO).

# ITER DIAGNOSTICO IDEALE

**TC ad alta  
definizione  
+ pancreas  
protocol**



**Ecografia  
laparoscopica  
nei casi dubbi**

# Molto importante

- **Morbilità della resezione della testa del pancreas: 10-45%**
- **Paziente con comorbilità significative**

**NECESSARIO EVITARE  
RESEZIONI INUTILI !**

## Tuttavia....

- **Esplorazione non vuol dire....  
resezione!**
- **Non ci sono analisi precise della  
morbilità legata alla SOLA  
laparotomia...**
- **Laparotomia = palliazione chirurgica  
(derivazione bilio-digestiva) ?**

# Tuttavia....

- **Mancano studi randomizzati**
- **Studi eseguiti da centri specializzati**
- **Dati non uniformi**
- **Non ben chiara qualità dell'imaging preoperatorio**
- **Studi cost-effectiveness molto limitati**
- **Mancano studi sulla qualità di vita dopo LUS ovvero laparotomia**

# Punti di discussione conclusivi

- **Valutazione oncologica iniziale al ricovero: prognosi favorevole a 6 mesi.**
- **Ma il paziente aveva una importante comorbidità cardiovascolare, pur con integrità cognitiva e funzionale.**

# Aspettativa di vita negli anziani

## Anni da vivere

### Uomini

### Donne

Età	70	75	80	85	90	95	70	75	80	85	90	95
<b>Robusto</b>	180	142	108	79	58	43	213	170	130	96	68	48
<b>Intermedio</b>	124	93	67	47	32	23	157	119	86	59	39	27
<b>Fragile</b>	67	49	33	22	15	10	95	68	46	29	18	17

Based on NCHS Life Tables of the United States 1997,

Adapted from Walter LC and Covinsky KE. JAMA 2001; 285: 2750-6

- **Campanello d'allarme di esito infausto (?): variazione CA 19-9 tra i due ricoveri 258 (GER) vs 1164 (CGE) (ricordiamo tuttavia la presenza di colangite).**
- **Avrebbe avuto senso ripetere una TC con tecnica spirale mirata alla valutazione della neoplasia?**
- **Il paziente è deceduto dopo due mesi dalla valutazione oncologica (prognosi superiore a sei mesi)**
- **Lo stato funzionale ha portato ad avere un atteggiamento più aggressivo.**
- **La patologia neoplastica è risultata determinate indipendentemente dallo stato funzionale.**

**Il paziente è deceduto per il tumore con la comorbilità**



**L'anziano robusto muore per il tumore (per questo motivo tutto il work-up diagnostico e terapeutico è stato finalizzato al controllo della malattia neoplastica)**

**(diverso sarebbe stato l'approccio in un paziente fragile con la stessa malattia tumorale).**

**“.. Before I came here I was confused about this subject. After listening to your lecture I am still confused but at a higher level..”**

**Enrico Fermi**

**1938 Nobel Laureate in Physics**

Best Wishes  
for a happy  
Christmas



MAILED ONLY  
COVERED BY  
THE  
POSTAL SERVICE

Allen  
H. Capp's studio